

ORIGINAL ARTICLES

Clinical Applications of the 532-nm Diode Laser for the Treatment of Facial Telangiectasia and Pigmented Lesions: Literature Review, History, and Discussion of Clinical Experience

Joseph Niamtu, III, DDS

Introduction: Facial telangiectasias are common lesions resulting from multiple factors. Multiple therapies and devices have been used for the treatment of facial telangiectasia with varied success and complication rates. The 532-nm diode (diode-pumped, frequency-doubled Nd:YAG) laser is compared with other laser and nonlaser modalities for the office-based cosmetic surgery practice.

Materials and Methods: This article provides a literature review and examines the history of laser treatment of facial telangiectasia and the evolution of modern laser therapy. Clinical experience is also detailed in the treatment of facial telangiectasia and pigmented lesions.

Results: 532-nm diode lasers are lightweight, extremely portable systems that are effective in the treatment of facial telangiectasia and various pigmented lesions. When compared to other popular modalities and laser wavelengths, the 532-nm diode laser can successfully treat facial telangiectasia and some pigmented facial lesions with less chance of collateral tissue damage and resultant complications.

Discussion: The 532-nm diode laser is representative of technological innovations that enable small, lightweight, and affordable lasers to be used by the office-based cosmetic surgeon. Distinct advantages are evident when it is compared with other wavelength lasers. Because of the smaller spot size and depth of penetration, this laser also has treatment limitations; however, it provides a welcomed addition to the armamentarium for the surgeon treating facial ectatic and pigmented lesions.

Conclusion: Because of its demonstrated clinical effectiveness, ease of use, and lack of resultant purpura, as well as affordability and portability, this laser is well suited for the office-based cosmetic practice.

Prior to the advent of laser technology, fine-wire cautery, cryotherapy, and sclerotherapy were used to treat facial telangiectasia.¹ Fine-wire radiosurgery can be very effective, but is operator sensitive.² In addition, it can be painful, and it destroys normal tissue surrounding the vessels. Because of the nonspecific tissue destruction, a significant risk of scarring exists. The use of cautery or radiofrequency also causes acute hemorrhaging of the vessels that is difficult to control and complicates visualization of surrounding telangiectasias.

Some of the earliest laser treatments for facial telangiectasia were performed with continuous wave CO₂ (10600 nm) and argon (488 and 514 nm) lasers, as well as Nd:YAG (1064 nm) systems.^{3,4} Although successful outcomes were reported, the CO₂ laser destroyed the ectatic vascular tissue as well as the overlying epidermis in a nonselective fashion.⁵ The argon laser, which emits a mixed blue and green light selective for hemoglobin and melanin, also destroyed ectatic vessels and the overlying epidermis.⁵ This nonselective heat dissipation resulted in a high incidence of scarring and hypopigmentation or hyperpigmentation.⁶ These lasers were, in effect, sophisticated forms of electrocautery.⁷

In 1983 when Anderson and colleagues,⁸ in a classic paper, described the concept of selective photothermolysis, they hypothesized that selective thermolysis could be predicted by choosing the appropriate wavelength, pulse duration, and pulse energy for a particular chromophore target.⁹ This simple theory revolutionized laser surgery. The 2 key conclusions were that the wavelength of the laser light must be absorbed by the target in order to have a treatment effect and that the laser energy must be confined to the intended target to spare the surrounding tissue from damage. As previously stated, the target for vascular lesions is oxyhemoglobin. The absorption peaks for oxyhemoglobin are approximately 418, 542, and 577 nm.

The theory of selective photothermolysis spurred the development of flashlamp-pumped, pulsed-dye, and copper-vapor lasers. These lasers emit light between

Received for publication December 18, 2000.

Dr Niamtu is in group private practice of Oral/Maxillofacial and Cosmetic Facial Surgery in Richmond, Va.

Corresponding author: Joseph Niamtu III, DDS, 10230 Cherokee Rd, Richmond, VA 23235 (e-mail: niamtu@niamtu.com).

I certify that I have no financial interest in any way with any of the devices or companies mentioned.



Figure 1. *The Diolite 532 nm diode laser is a compact, portable, and solid-state unit weighing only 6.8 kg.*

577 and 585 nm. These wavelengths are selectively absorbed by oxyhemoglobin, thus destroying the ectatic vessel with minimal damage to the underlying tissue. This type of laser differs from previous lasers by emitting light in pulses rather than a continuous beam.⁷

In addition to the pulses, the time between each pulse allows thermal cooling of the target chromophore. If the pulse width is equal to or less than the thermal relaxation time (TRT) of the telangiectatic vessel (the time during which 50% of the incident heat has transferred out of the vessel to adjacent tissues), the resultant thermal damage will be confined to the vessel.¹⁰ Having a pulse duration that is shorter than the TRT of the treated vessel prevents the energy from dissipating too far beyond the targeted vessel. For vessels as small as 50–75 μm in diameter, the TRT is approximately 1 millisecond.¹⁰ Larger vessels, such as those found on the ala, have a much longer TRT. A vessel with a diameter of 300 μm has a TRT of approximately 42 milliseconds, about 10 times that of a vessel one third its size. Vessels with a diameter of 1000 μm (1 mm) have a TRT of about 500 milliseconds.¹⁰

The 585-nm flashlamp-pumped, pulsed-dye laser has become the gold standard by which other vascular lasers are judged. The flashlamp-pumped, pulsed-dye laser has the significant drawback of posttreatment purpura, which is difficult to conceal and can persist for up to 14 days. Other clinical drawbacks of the pulsed-dye laser include costly field service for tube or dye replacements, mirror collimation, and overheating of the machine and the treatment room.

532-nm Laser Physics

Just as transistors made vacuum tubes obsolete, semiconductor diode-pumped lasers are replacing vacuum tubes and flashlamp-pumped lasers. The Diolite 532-nm diode laser (Iridex Inc, Mountain View, Calif) is a lightweight, portable laser about the size of a video cassette recorder. The laser weighs only 6.8 kg and uses standard wall power, consuming less than 350 W of electrical power (Figure 1). There is no installation cost, and operating costs are almost nonexistent. The energy-based control system delivers the specific treatment fluence in laser pulses between 10 and 25 milliseconds.

The 532-nm wavelength is a green light and is obtained by a process known as frequency doubling (FD). Diodes are commonly used in many devices such as bar code readers and compact disc players. They are typically made of gallium arsenide (GaAs) and can be mixed with other elements to change their characteristics. A high-powered diode laser at 808 nm is used to optically pump a Nd:YAG crystal that produces 1064-nm light (Figure 2). This light is then focused onto a potassium titanyl phosphate (KTP) crystal to double its frequency and split the wavelength in half, producing a 532-nm wavelength. A red diode-aiming beam is added to target the 532-nm beam. The diode-pumped, frequency-doubled Nd:YAG laser is referred to as the DP FD Nd:YAG laser. This laser is also called a millisecond Nd:YAG to represent the ability of the laser to vary the pulse duration according to the vessel diameter and location that determine the TRT. The absorption of green light at 532 nm by oxyhemoglobin is very high, resulting in a high extinction

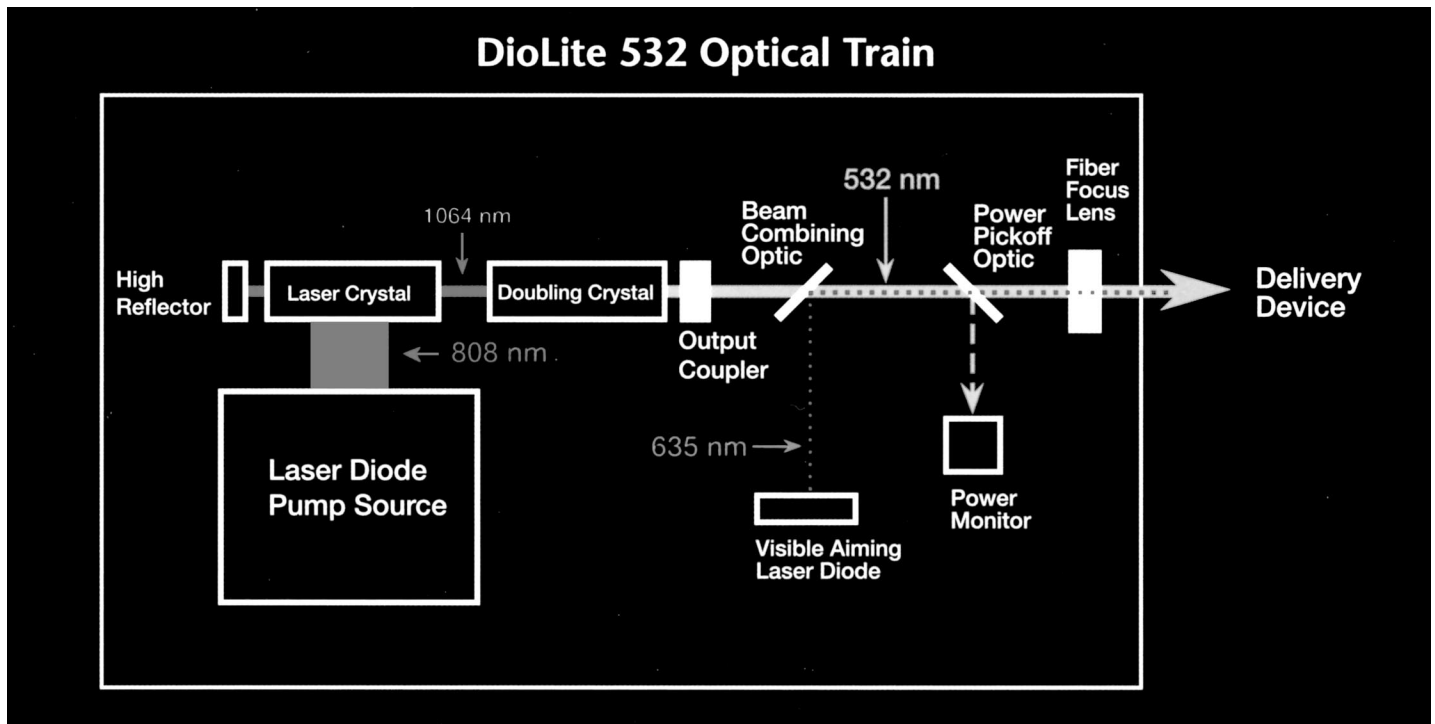


Figure 2. This diagram illustrates the 532-nm diode laser optical train.

coefficient. The 532-nm green light wavelength is also absorbed by melanin. This is an advantage, for the 532-nm (DP FD Nd:YAG) laser can be used to treat pigmented lesions. Although used frequently, care should be taken when treating darker skin to avoid epidermal injury. The 532-nm diode (DP FD Nd:YAG) laser produces a 532-nm wavelength that is strongly absorbed by oxyhemoglobin. The pulsed-dye laser at 585 nm and the Krypton laser at 568 nm also target oxyhemoglobin. All 3 lasers penetrate tissues to a similar depth and react with oxyhemoglobin essentially the same way. With similar absorption coefficients, there are in fact significant differences that are largely the effect of pulse durations (Figure 3).

Pulsed-dye lasers produce pulse durations of 450 microseconds to 1.5 milliseconds. These pulse durations produce selective treatment of vascular lesions; however, the 585-nm flashlamp-pumped, pulsed-dye laser causes violent vaporization of blood within the vessel. The short pulses of 450 microseconds (0.45 milliseconds) heat the oxyhemoglobin so rapidly that it creates a steam bubble and bursts holes in the vessels. This destruction of the vessel, with resultant extravasation of red blood cells, gives rise to clinical purpura (Figure 4).

The Krypton laser produces long pulse durations of 0.1 or 0.2 seconds, which are beyond the TRT of most facial vessels, allowing for thermal conduction into the surrounding tissue. These extended exposures do not cause purpura, but allow conduction loss from the target vessel to the surrounding tissue, increasing non-specific injury.

In contrast, the 532-nm diode (DP FD Nd:YAG) laser delivers pulse durations from 1 to 100 milliseconds that provide selective photothermolysis without purpura. Typically used between 10 and 25 milliseconds, the 532-nm diode (DP FD Nd:YAG) laser uses moderate pulses targeting the abnormal vascular structures while sparing the normal capillaries, hence producing no purpura. The much longer pulse duration of 1–100 milliseconds seems to be well matched to the TRT of most facial vessels. It is this longer pulse of the 532-nm diode (DP FD Nd:YAG) laser that spares gross vessel damage.

Those with experience with the 532-nm diode (DP FD Nd:YAG) laser are familiar with the immediate disappearance of the ectatic vessel after laser-light exposure. Active or passive vasoconstriction cannot explain the total resolution or emptying of the vessel lumen. With the longer 532-nm diode (DP FD Nd:YAG) laser pulses, the blood is more gently heated and damages the endothelial cells, but it does not burst the vessel. There are theories that state that the laser energy creates a small steam bubble that expands along the axis of the vessel, clearing the lumen and pushing a column of hot blood along the vessel. As the vessel cools during its TRT, the vapor bubble condenses and collapses the vessel wall. Thermal coagulation of the blood, now ejected well beyond the actual exposure site, creates an intravascular plug, leaving an empty, thermally damaged lumen at and around the site of the laser exposure. This process is significant because gentle intravascular vaporization forces extremely hot

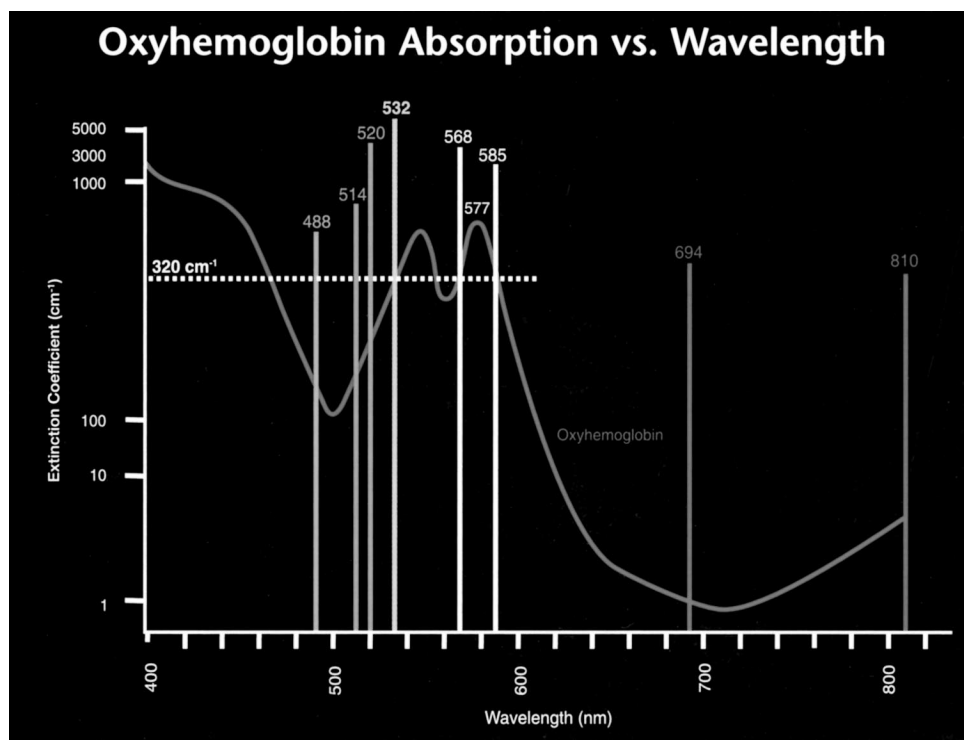


Figure 3. The oxyhemoglobin absorption vs wavelength chart is illustrated showing absorption coefficients of various wavelengths.

blood to travel millimeters beyond the actual site of laser impact.¹¹

Multiple studies have shown the 532-nm diode (DP FD Nd:YAG) laser to be effective in treating facial telangiectasia.^{6,11–13} Cassuto et al¹¹ showed that 93% of patients (62 of 66) obtained 75–100% clearance. The remaining 4 of 66 had 50–75% clearance, but were satisfied. Hevia¹⁴ compared the 532-nm diode (DP FD Nd:YAG) laser with the 585-nm flashlamp-pumped, pulsed-dye laser and found no significant clinical differences in the treatment of facial telangiectasia, but he did report statistical differences between the 2 lasers. Patients reported a significantly greater degree of swelling, bruising, pain, and redness after the flashlamp-pumped, pulsed-dye laser. Hevia concluded that the 532-nm diode (DP FD Nd:YAG) laser appeared to be the optimal choice for the treatment of facial telangiectasia because of its effectiveness combined with patient comfort. This study was well constructed, but with a small sample size ($N = 15$ patients). No permanent pathologic skin changes were noted.

Clinical Applications

Vascular Pathology

Millions of people, especially those with Fitzpatrick skin-types 1 and 2, develop telangiectasias. The nasal ala and medial cheeks are the most commonly involved areas. Telangiectasias are permanently dilated cutaneous blood vessels visible to the naked eye and by definition do not exceed 1 mm in diameter. On the

basis of their appearance, telangiectasias are simple (linear), arborizing, spider- or star-shaped, and punctate (papular) lesions.¹⁵ Spider telangiectasias consist of red radiating arms stretching from a central pulsating arteriole. Histologically, they represent dilated or ectatic vessels in the superficial papillary dermal plexus. Thin, wiry, and red telangiectasias extend from arterioles or from the arterial side of a capillary loop. Cordlike, blue vessels arise from venules or from the venous side of a capillary loop.¹⁶ Red capillary telangiectasias stretching from the capillary loop may also become blue with time as hydrostatic pressure and venous backflow increase.¹⁷ Telangiectasias occur in up to 48% of healthy children and 15% of normal adults. Telangiectasias of the lower extremities occur in 29–41% of women and 6–15% of men.²⁰ Telangiectasias derive from various factors.¹⁶ Some intrinsic factors include congenital causes, primary cutaneous disorders (eg, Rosacea), systemic disease (eg, collagen vascular disease), Cushing's disease, metastatic carcinoma, pregnancy, venous incompetency, and inherited genetic disorders such as hereditary hemorrhagic telangiectasia. Some extrinsic factors can be drug induced by estrogens or chronic steroid use. Other extrinsic factors include actinic and radiation dermatitis, postsurgical rhinoplasty (wound closure under tension), radiotherapy, and trauma.^{21,22} Vasoactive mediators have been implicated in vascular neogenesis in the formation of telangiectasia. The new vessels occur as a response to anoxia, alcohol, chemicals, hormones, direct trauma,

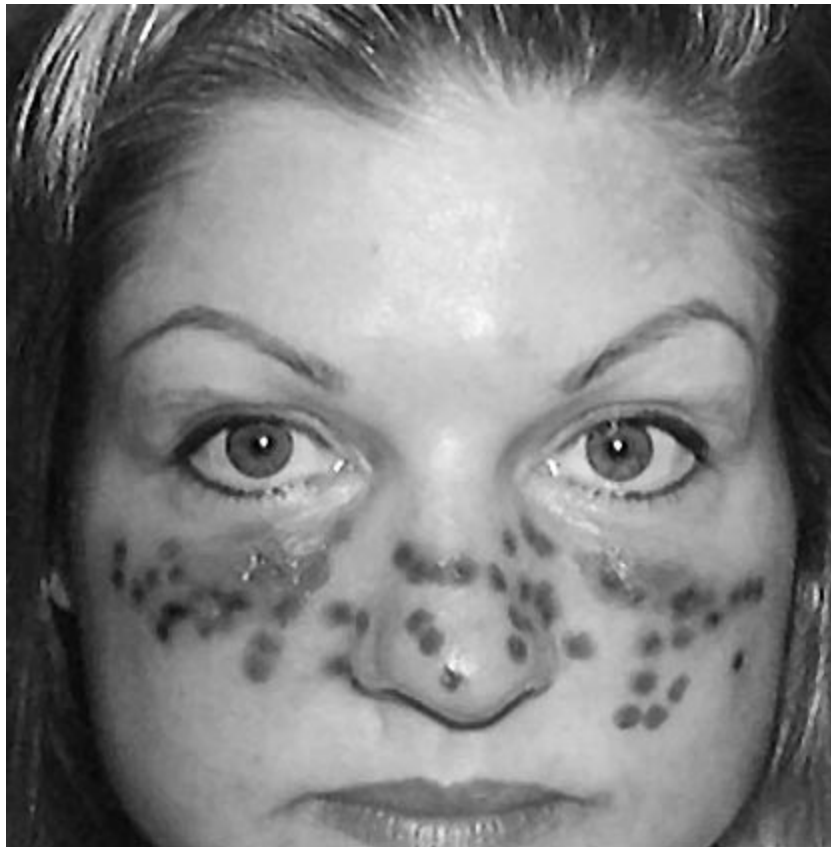

Figure 4. *Clinical purpura from 585-nm pulsed-dye laser treatment. These purpura are difficult to conceal and are a major drawback for patients.*

sinus infection,²³ and other physical factors that result in angiogenesis.^{24,25} It should always be kept in mind that the presence of numerous telangiectasias can indicate dermatologic or systemic internal disease.

The Iridex 532-nm diode (DP FD Nd:YAG) laser comes complete with a polarizing magnified headlight (Seymour Light XL-2000 Illumination System) that significantly enhances the contrast of the vascular lesions (Figure 5). By eliminating the glare and reflection, the surgeon has the illusion of seeing beneath the skin. This incorporates a retractable magnifying loop for improved visualization. In addition, the 532-nm diode (DP FD Nd:YAG) laser requires wavelength-specific eye protection for the patient and doctor. The patient wears opaque metal goggles, and the operator and assistants wear safety glasses that are able to absorb the laser wavelength.

The laser is accompanied by 5 separate handpieces that deliver spot sizes of 200, 500, 700, 1000, and 1400 μm , respectively (Figure 1). The laser is used on various settings to treat vascular and pigmented lesions. Telangiectasias, cherry angiomas, spider angiomas, and smaller port-wine stains are vascular lesions readily and predictably treated with the 532-nm wavelength. A larger spot handpiece treats the same lesion with less energy density. Ideally, the spot size utilized should match the diameter of the vessels being treated.

A general dictum is that if a vessel is large enough to accommodate a needle, it is too large for this type of laser. The author's experience has shown more pain perception by the patient with the larger spot sizes. A computerized scanning device is also available for the Diolite laser to treat larger areas or lesions, but the author has no experience with this device.

Anesthesia

Although most surgeons do not use any type of anesthesia, this is not necessarily in the best interest of the patient. The author feels that the treatment pain is similar to a BOTOX injection, and most patients can tolerate the smaller spot sizes with no anesthetic; however, some patients react poorly or are uncomfortable during treatment. Single laser pulses are activated by tapping the footswitch intermittently, causing a minor, slightly delayed pain, which the author describes to the patient as a rubber band snap. Holding down the foot switch will cause a continuous but adjustable repeat rate. Slower repetition rates (4–7 Hz) usually result in less discomfort. Using the 15 Hz repeat provides faster treatment, but it is also considerably more uncomfortable for the patient. The use of a thin layer of refrigerated, water-based gel, such as aloe vera, will provide a thermal sink for the skin, will result in greater comfort, and will reduce the risks of epidermal injury.



Figure 5. A magnified polarizing headlight is used to more clearly contrast the individual vessels.

When treating very sensitive areas such as the nasal alae, upper lip, or periorbital areas, the author frequently utilizes local anesthetic blocks. An infraorbital nerve block is used by injecting 1–2 mL of 2% lidocaine 1:100 000 epinephrine at the infraorbital foramina (Figure 6). This block can be performed transcutaneously or intraorally. Transcutaneous injection is performed in the midline of the pupil approximately 5–7 mm below the inferior orbital rim. Intraorally, the needle is placed through the vestibular mucosa between the cuspid and first bicuspid about 20 mm above the tooth crowns. This blocks the lower eyelid, the upper lip, the lateral nose, and most of the nasal tip and the anterior cheek. Areas not amenable to nerve block can be treated with local infiltration.

Techniques and Settings

Any residual makeup is removed, and a test spot is performed on an inconspicuous area of the face or neck to evaluate the patient's pain response and the selected procedural parameters. Special care should be used when treating tan or pigmented skin, as a potential for epidermal injury exists because of an affinity of the 532-nm wavelength for melanin. Generally, a thin layer of water-based gel and moderate energy settings are adequate to prevent thermal injury. Pigmentary dyschromia, if it occurs, is transient and can typically be treated with hydroquinone or similar agents.

The 532-nm laser wavelength penetrates to a distance of about 1.5 mm. Other wavelengths such as the 800 nm and 1064 nm penetrate more deeply and can be more effective in the treatment of deeper vessels,

but will be less effective in the treatment of small diameter vessels of the face. Because the 532-diode laser can penetrate 1.5 mm, the eyelids are never treated without metal eyeshields.

The handpiece size is matched to the diameter of the vessels being treated. The energy density is chosen by the lowest density needed to attain the disappearance of the vessels. Most frequently, the author uses the 700- μm handpiece with a setting of 3 W and 24 J/cm². Most surgeons begin with a repeat rate of 4 Hz and increase this according to the patient's comfort. The handpiece is moved quickly because the induced flushing will obscure smaller telangiectasias. This is important to communicate with the patient as the ensuing erythema can lead them to think they are treated to resolution only to find that their vessels reappear several hours or days later.

The basic treatment technique is simple. The laser spot is used to trace individual vessels to an end point of disappearance (Figure 7). The laser traces the individual vessels and causes them to collapse, which is the clinical endpoint. Some vessels may require several passes, and the skin should be allowed to cool between passes. A moderate energy density such as 16 J/cm² is initially used, increasing the energy density until vessel collapse is observed. Excessive thermal energy can cause linear hypopigmentation, hyperpigmentation, and possibly atrophic scarring.²⁶

Arborized telangiectasias are treated by starting at the branching and working toward the center, which is painted with several pulses. Cherry angiomas, or round punctate lesions, are treated with multiple pulses at the

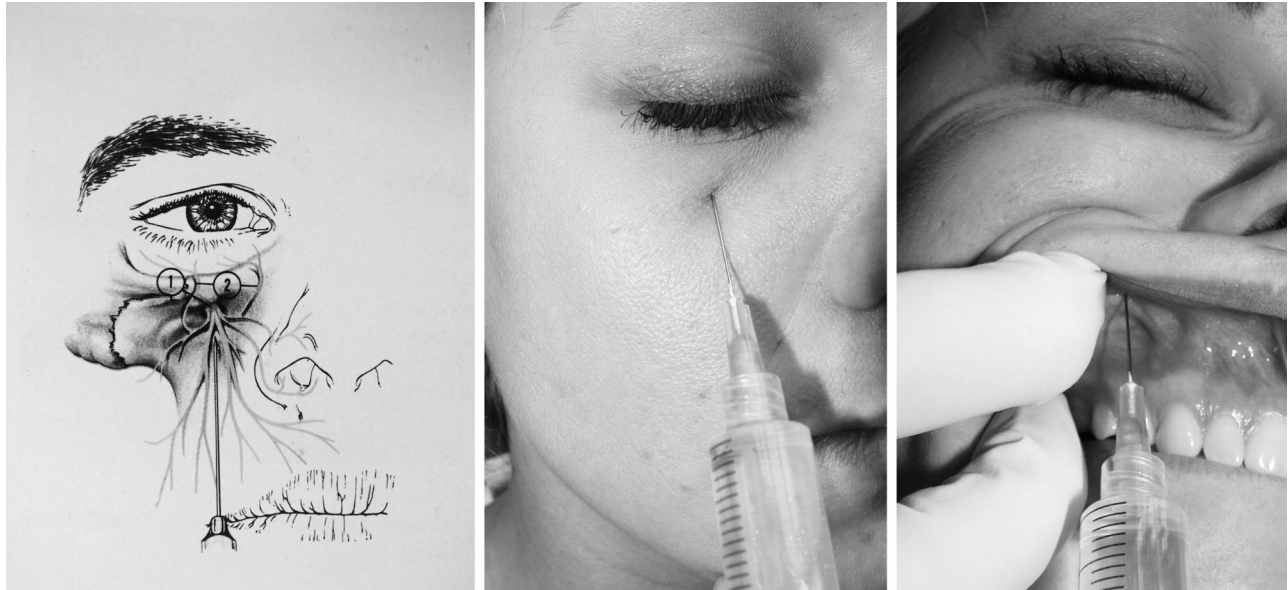

Figure 6. Local anesthesia block of the infraorbital nerve is effective in anesthetizing common areas of facial telangiectasias. The above photo illustrates the infraorbital nerve anatomy as well as transcutaneous and intraoral anesthetic technique.



Figure 7. The individual ectatic vessels are traced with the 532-nm laser light. The above photo illustrates the 1.4-mm handpiece.

center of the lesion (Figure 8). Matted ectatic vessels or port-wine stains are better treated with a larger spot size and lower fluence (Figure 9). This treatment usually requires some form of anesthesia. A computerized scanning device is also available for large areas or lesions.

The 532-nm diode (DP FD Nd:YAG) laser will cause immediate erythema and edema that usually only lasts a few hours (Figure 10). Prolonged treatments become difficult as the erythema obstructs smaller vessels. For these reasons, multiple short sessions are often used. Whereas most vessels can be adequately treated with a single session, some vessels are recalcitrant or recurrent and can require additional sessions.

Because the epidermal integrity is not violated, no specific postoperative treatment is necessary, and makeup can be worn immediately. If excessive thermal energy is induced, crusting or ulceration can appear and is treated with a triple antibiotic ointment for several days. Cool compresses are used for edema and discomfort; analgesics have not been necessary. Treatment sessions are spaced at least 2 weeks apart when aggressive treatment is used or sensitive skin response is seen. The 532-nm diode (DP FD Nd:YAG) laser is also used to treat nonfacial pigmented lesions on nonfacial areas and some promise exists for leg veins.¹¹

Treatment of Pigmented Lesions

The absorption spectrum of melanin includes the ultraviolet, visible, and near-infrared portions of the electromagnetic spectrum. Because of this, virtually every wavelength along the spectrum can theoretically be used to target melanin.²⁷ Melanosomes are much smaller than blood vessels (10 vs 100 μm) and a much

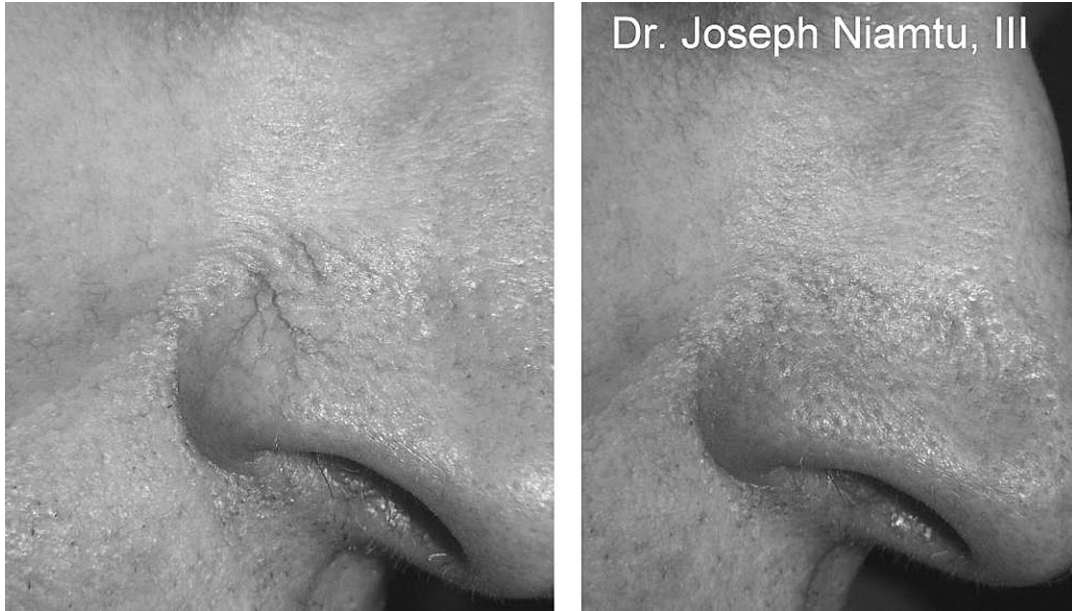


Figure 8. Before and immediately postlaser treatment images of an arborizing telangiectasia of the lateral nose.

shorter pulse duration is required as compared to telangiectasias.²⁷

Pigmented lesions such as lentigines, keratoses, ephelides (freckles), and dermatosis papulosa nigra have been successfully treated with the 532-nm wavelength (Figure 11).²⁸ Early hypertrophic scarring and keloids that possess significant vascularity have been successfully treated.²⁸ For most macular lesions, such as lentigines, the endpoint is a uniform gray color and a popping sound that occurs when a tissue becomes plasmoid (Figure 12).²⁸

The pigmented lesions exfoliate over 1–2 weeks (Figure 13). Larger or thicker lesions may need retreatment until clinical clearing is achieved. Lesions with varied areas of pigmentation will respond differently to treatment in that the darker areas will absorb more laser energy. Nonpigmented lesions have been treated with artificial chromophore such as ink.²⁸

Complications

As with any laser, attention to clinical endpoint is paramount to successful treatment. Undertreatment

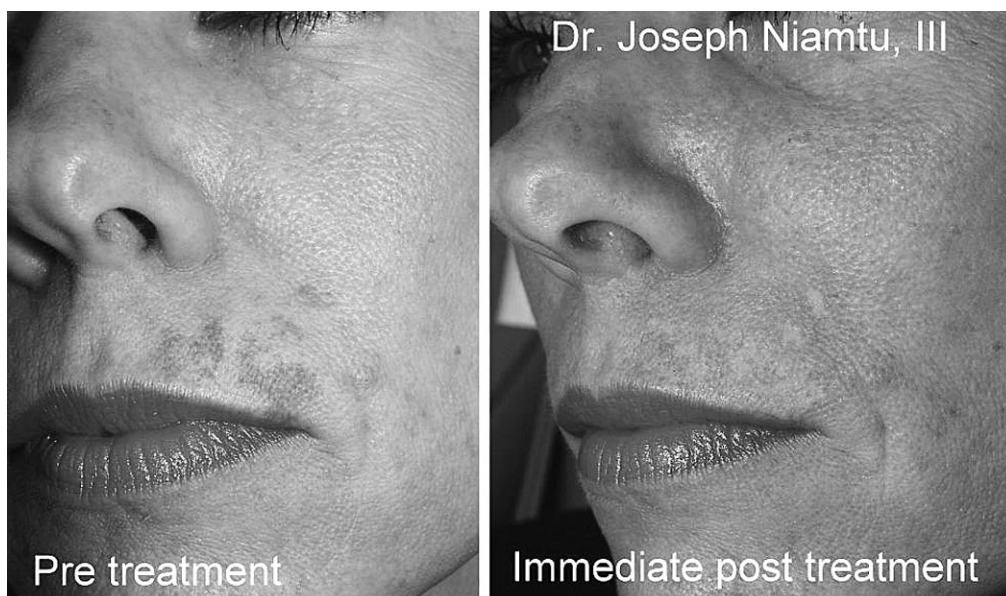

Figure 9. Before and immediate postoperative photo of a small port-wine stain of the upper lip. This lesion required 3 treatments with the 532-nm laser for resolution.

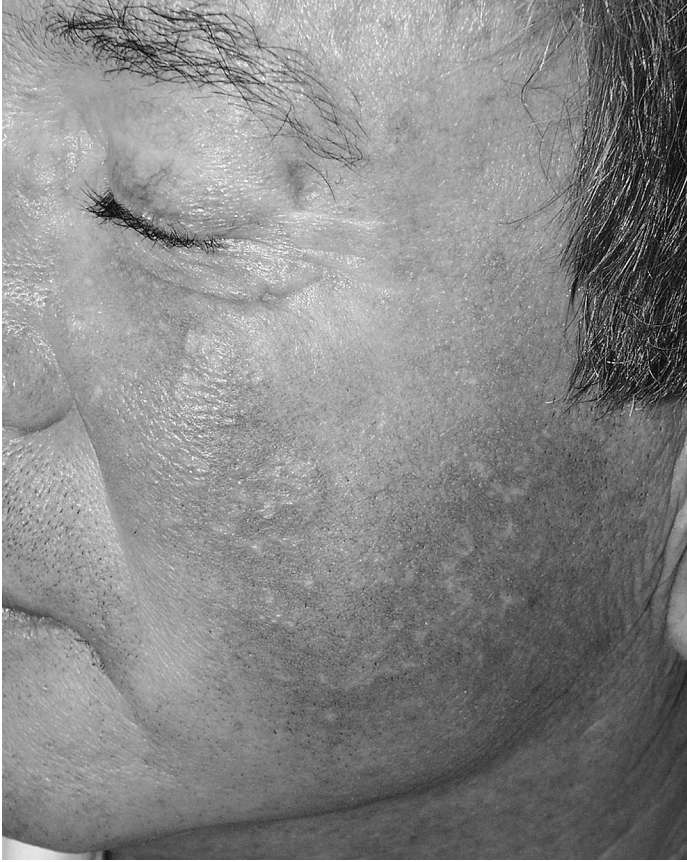

Figure 10. *Erythema manifests immediately during the 532-nm treatment. Localized edema is common in aggressive treatment, beginning soon after treatment and lasting for several hours.*

will not remove the ectatic lesions, and overtreatment can cause linear hypopigmentation, hyperpigmentation, and possible scarring because of extravascular tissue destruction. Attention to the clinical endpoint of vessel collapse is the best treatment indicator. Test spots and conservative initial treatment are recommended until the patient's healing response is determined. Special care should be exercised in the areas

of the upper lip, mandibular border, and neck that are prone to scarring. As mentioned earlier, the 532-nm diode (DP FD Nd:YAG) laser has a high affinity for melanin. Conservative parameters should be used when treating patients with suntans or darker skin. The manufacturer recommends not treating suntanned skin and not tanning 3 months after treatment. The reactive hyperpigmentation that could arise from tanned skin will usually heal, but like any laser that targets melanin, tanned skin should be treated with caution.

The 585-nm flashlamp-pumped, pulsed-dye laser has a larger spot size that enables more rapid treatment. In contrast, the 532-nm diode (DP FD Nd:YAG) laser has a much smaller spot size and tracing the individual vessels with it requires more manual dexterity when compared to a laser with a larger spot size. The use of magnification and individual vessel tracing is also more tedious than the larger areas covered with the 585-nm handpiece.

Finally, 532-nm diode laser therapy may require multiple sessions. The author's experience shows approximately a 50% resolution with a single treatment. Individuals prone to telangiectasia, or those who frequently pursue physical exercise or consume alcohol, may experience reformation of telangiectasias. In these patients, 532-nm diode laser treatment should be thought of as maintenance therapy because future treatments may be necessary.

Nd:YAG Frequency Doubled Lasers

Other 532-nm wavelength lasers exist for the successful treatment of telangiectasias and pigmented lesions. The VersaPulse laser (Coherent Medical Group, Palo Alto, Calif) offers larger spot sizes (2–10 mm) and therefore must be very high powered to provide adequate energy densities. This laser is used for treating facial and lower extremity telangiectasia. In contrast to the 6.8-kg Diolite, 532-nm diode laser, the VersaPulse is a large 135-kg unit. The VersaPulse also has a water-cooled handpiece, which may be awkward around contours such as the nose.

The Aura 532-nm KTP laser (Laserscope, San Jose, Calif) is a flashlamp-pumped, frequency-doubled Nd:

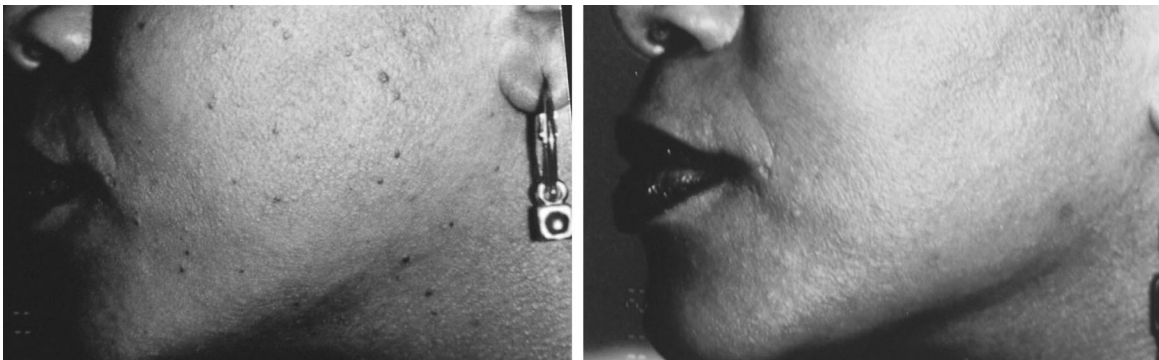


Figure 11. *Shows before and after images of successful treatment of multiple dermatosis papulosa nigra lesions on an African-American patient.*

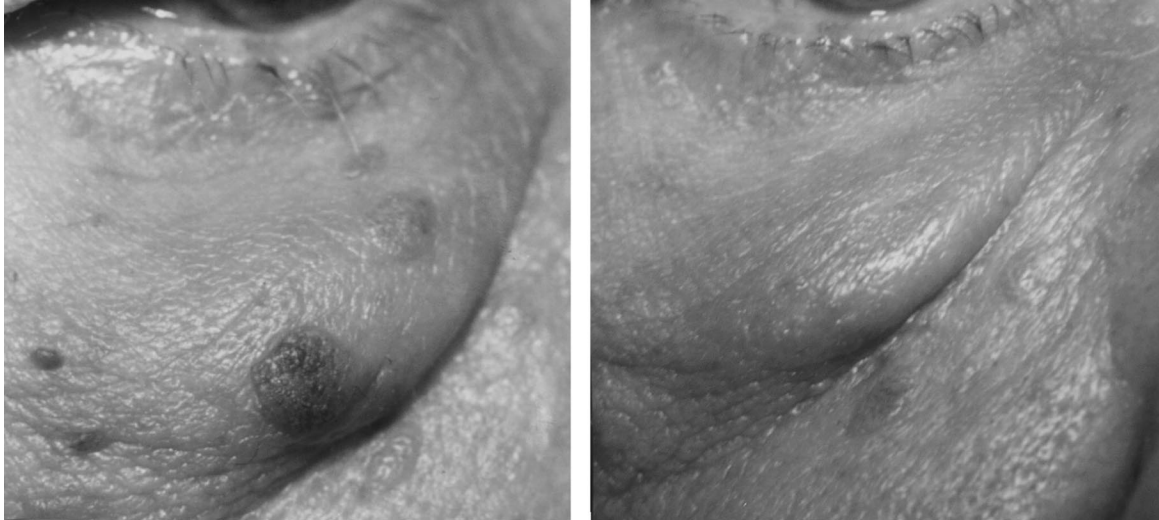

Figure 12. The endpoint of treating pigmented lesions is a uniform gray color, as shown above. A popping sound also is indicative of sufficient laser exposure.

YAG laser. Although the laser is similar to the Diolite 532 laser, it is significantly larger at 27 kg. This laser is also effective in the treatment of facial telangiectasia.

Discussion

Multiple 532-nm lasers are available for the treatment of telangiectasias and pigmented lesions. The Iridex Diolite 532 (DP FD Nd:YAG) laser is an extremely portable solid-state laser that enables transportation between offices or treatment rooms. The small handpieces are very flexible and are well suited for the precision tracing of individual telangiectasias. The 532-nm wavelength has been shown in multiple studies to be effective for the treatment of facial telangiectasia, minor vascular lesions, and some pigmented lesions.^{6,11-13} The portability, affordability, ease of use, and efficacy of the 532-nm diode laser makes it well suited for office-based cosmetic surgery practice.

References

1. McBurney EJ. Carbon dioxide laser treatment of dermatologic lesions. *South Med J.* 1978;71:795-797.
2. Niamtu, J. *Oral and Maxillofacial Surgery Clinics of North America.* Philadelphia, PA: W.B. Saunders; 2000.
3. Landthaler M, Hohenleutner U, El Raheem TA. Therapy of vascular lesions in the head and neck area by means of argon, Nd:YAG, CO₂ and flashlamp-pumped pulsed dye lasers. *Adv Otorhinolaryngol.* 1995;49:81-86.
4. Landthaler M, Haina D, Brunner R, Waidelich W, Braun-Falco O. Neodymium-YAG laser therapy for vascular lesions. *J Am Acad Dermatol.* 1986;14:107-117.
5. Dixon JA, Huether S, Rotering R. Hypertrophic scarring in argon laser treatment of port-wine stains. *Plast Reconstr Surg.* 1984;73:771-780.
6. Goldberg DJ, Meine JG. A comparison of four

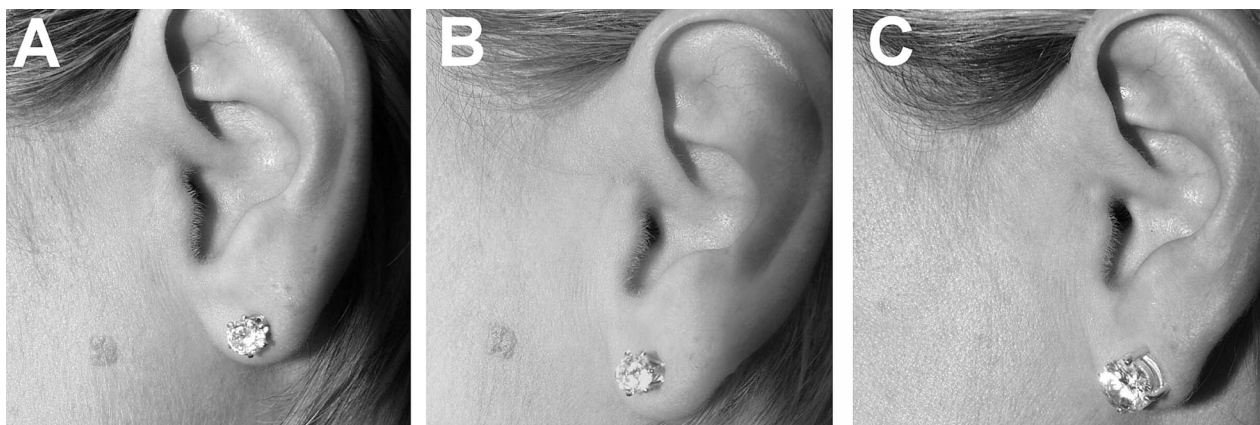

Figure 13. Shows the successful treatment of multiple seborrheic keratoses of the right cheek. (Photo courtesy of Thomas Spoor, MD)

frequency-doubled Nd:YAG (532 nm) laser systems for treatment of facial telangiectases. *Dermatol Surg.* 1999;25:463–467.

7. Key MJ, Warner M. Selective destruction of facial telangiectasia using a copper vapor laser. *Arch Otolaryngol Head Neck Surg.* 1992;118:509–513.

8. Anderson RR, Jaenicke KF, Parrish JA. Mechanisms of selective vascular changes caused by dye lasers. *Lasers Surg Med.* 1983;3:211–215.

9. Anderson RR, Parrish JA. Selective photothermolysis: precise microsurgery by selective absorption of pulsed radiation. *Science.* 1983;220:524–527.

10. Anderson RR, Parrish JA. Microvasculature can be selectively damaged using dye lasers: a basic theory and experimental evidence in human skin. *Lasers Surg Med.* 1981;1:263–276.

11. Cassuto DA, Ancona DM, Emanuelli G. Treatment of facial telangiectasias with a diode-pumped Nd:YAG laser at 532 nm. *J Cutan Laser Ther.* 2000; 2: 141–146.

12. Silver BE, Livshots YL. Preliminary experience with the KTP/532 nm laser in the treatment of facial telangiectasis. *Cosm Dermatol.* 1997;9:61–64.

13. West TB, Alster TB. Comparison of the long-pulse dye (590–595 nm) and KTP (532 nm) lasers in the treatment of facial and leg telangiectasias. *Dermatol Surg.* 1999;24:221–226.

14. Hevia O. New laser treatment for facial telangiectasia: a randomized study. *Cosm Dermatol.* 1997; 10:47–52.

15. Redisch W, Pelzer RH. Localized vascular dilations of the human skin: capillary microscopy and related studies. *Am Heart J.* 1949;37:106–114.

16. Waldorf HA, Lask GP, Geronemus, RG. Laser treatment of telangiectasias. In: Alster TS, Apfelberg DB, eds. *Cosm Laser Surgery.* New York, NY: Wiley and Sons; 1996:71–107.

17. Merlen JF. Red telangiectasias, blue telangiectasias. *Soc Franc Phlebol.* 1970;22:167–174.

18. Bean WB. *Vascular spiders and related lesions of the skin.* Springfield, IL:Thomas; 1958.

19. Alderson MR. Spider Naevi—their incidence in healthy school children. *Arch Dis Child.* 1963;38:286–288.

20. Goldman MP, Fitzpatrick RE. Pulsed dye laser treatment of leg telangiectasias: with and without simultaneous sclerotherapy. *J Dermatol Surg Oncol.* 1990;16:338–344.

21. Goldman MP, Bennett RG. Treatment of telangiectasia: a review. *J Am Acad Dermatol.* 1987;17: 167–182.

22. Goldman MP, Weiss RA, Brody HJ. Treatment of facial telangiectasia with sclerotherapy, laser surgery, and/or electrodesiccation: a review. *J Dermatol Surg Oncol.* 1993;19:899–906.

23. Ayers S Jr, Burrows LA, Anderson NP. Generalized telangiectasias and sinus infection: a report of a case with cure by treatment of chronic sinusitis. *Arch Dermatol Syph.* 1931;26:56–59.

24. Goldman MP, Bennett RG. Treatment of telangiectasias: a review. *J Am Acad Dermatol.* 1987;17: 167–182.

25. Rapaport MJ, Rapaport V. Prolonged erythema after facial laser resurfacing or phenol peel secondary to corticosteroid addiction. *Dermatol Surg.* 1999;25: 781–785.

26. Hruza GJ. Commentary to “Treatment of essential telangiectasias with an intense pulsed light source (PhotoDerm VL).” *Dermatol Surg.* 1997;23:945–946.

27. Dover JS. How cutaneous lasers perform in practice. *Skin Aging.* 1998;10:22–27.

28. McCann DP, Spoor TC. Clinical effects of the 532nm diode laser for treating a variety of vascular and pigmented skin lesions. *Cosm Dermatol.* 2000;13: 25–28.