

Laser Tattoo Removal: Benefits and Caveats

MAURICE A. ADATTO

Dermatology Department, University Hospital Geneva, Geneva, Switzerland, and
Skinpulse Dermatology Centre, Geneva, Switzerland

Submitted: April 2004 · Accepted: August 2004

Summary

From the beginning of humanity, tattooing has existed but also the desire to remove them. After years of methods leaving scars, came the era of lasers. First confined to laboratories due to their size and complexity, the first available systems were still producing thermal damage and thus scarring and dyschromia. Within the last 10 years, Quality-switched (Q-switched) laser systems have been available, which leave minimal damage if any. They are able to remove some tattoos, depending on pigments used, without scarring, hypo or hyperpigmentation. Caution must be taken with the use of these lasers to avoid complications such as darkening. The user should also be aware that some pigments might resist laser treatment. A big effort must be made in the near future to find and promote safer inks, which will not resist the available laser systems of today.

Key words

Tattoo, pigment, laser, Q-switched laser, darkening, photoacoustic shock

Introduction

The origin of tattooing among humans is as old as humanity itself (1). Tattooed human bodies have been found, as old as 5,000 years BC for the Bronze Age hunter, (nick-named Ötzi), discovered on the borders of Austria and Italy, frozen into a glacier. Indirect proof of 35,000 years old also exists in the caves of Arcy-sur-Cure in France. When man was nomadic, tattooing carried a tribes' laws but within the advent of writing, this use has been lost. Nowadays, tattooing has become fashionable, but human beings still change their body images and evolve psychologically with age. With this comes the request to remove tattoos. The main reasons for removing tattoos are enhancement of self-esteem and social, work or family reasons (2).

The amateur tattoo can be done by any sharp object like a needle or a sharp piece of bone. The professional tattooing technique depends on the country where the tattoo is performed. In Japan, the artist usually uses needles put together into a wooden handle, called hari, while for the Polynesian technique uses a sharp rake held by a handle that the artist will tap using a rigid piece of bamboo. In the western world the artist will use preferably the electric tattooing machine developed by Riley at the end of the 19th century. It consists of an electric motor driving a crankshaft similar to that of a sewing machine, which operates a metal stylus with a single needle or array of needles at its tip. The pigment is injected just below the epidermis and within ten to fourteen days tends to migrate deeper into the dermis for as an yet unknown reason.

Pigment can sometimes be found into the subcutaneous fat, tendon sheath and lymph nodes.

The phenomenon of tattooing has become more and more popular in the last 25 years. To the traditional decorative tattoo we have to add the so called “permanent makeup” which is nothing else but tattoo on the face, usually on the eyebrow, eyelids and lips. A recent survey done in Germany showed that 23% of the population aged 15 to 29 has at least one tattoo. Many different kinds of removal methods have been used throughout the centuries, such as chemical (3, 4), mechanical (5), surgical (6) and thermal (7). All these techniques left some kind of hypo or hyperpigmentation as well as scarring. With the advent of lasers in the late 1960s the outcome of tattoo removal completely changed. Due to its specific absorption by the pigment itself, the actual gold standard for tattoo removal are Q-switched lasers. We will report here our almost 15 year experience with these lasers, with emphasis on the benefits but also on the caveats of their use.

The old age of lasers

The first usable laser was a ruby that was developed by Maiman in 1960 (8). After having used the ruby laser on normal skin (9), Leon Goldman published his first report of the use of a Q-switched ruby laser on a tattoo (10). Encouraged by the good results, he then published a study comparing the effects of three lasers on tattoos, Q-switched ruby, Nd-YAG and Argon. The results were remarkable, especially the Q-switched ruby, with hypertrophic scarring in only 3 patients out of a total of 116 (1.85%). Unfortunately, though, this study makes no mention of the cosmetic results with respect to percentage pigment clearance. Though the results of the early work of Goldman et al. were encouraging with the Q-switched ruby laser, the technique was abandoned for almost 20 years. The reasons were mainly technical and commercial. The Q-switched ruby laser at this time, was expensive to buy and maintain. It was more a lab system than a laser which could be used in daily dermatological clinics.

During the 1970s and 80s, two laser systems, called Continuous Wave (CW), CO₂ and Argon, became popular among independent practitioners. They were small, affordable and could be used for multiple

dermatological indications. The CW CO₂ was used as an ablative tool for various indications (11) and the CW argon was the first laser used to treat vascular conditions, e.g. port-wine stains (12). One study resumes the final cosmetic outcome in removing tattoos with the CW CO₂ laser (13). Even though the CO₂ laser gave more acceptable results than chemical or mechanical methods, there was still unacceptable scarring. CW lasers were capable of removing pigmented lesions by ablating or coagulating superficial portions of the skin, but their non-specific tissue effect often led to unpredictable textural or pigmentary changes (14, 15).

Q-switched laser and tattoo particles interaction

In 1983 Anderson and Parrish proposed a theory for laser-induced injury confined to microscopic sites of selective light absorption in the skin, such as blood vessels and pigmented cells or tattoo particles, with minimal damage to the surrounding tissues. This theory of selective photothermolysis and the concept of thermal relaxation time revolutionised cutaneous laser therapy (16). Tattoo pigments, which consist of insoluble, sub-micrometers – sized particles that are phagocytosed by dermal cells, react almost the same way as melanosomes. Tattoo particles, sometimes grouped in granules and packed into vacuoles from 0.1 to 10 microns in diameter, are endocytosed by fibroblasts as well as macrophages in the dermis and sometimes in the subcutis. The smaller size groups (up to 0.20 microns in diameter) tend to be in the fibroblasts cytoplasm while the larger ones (up to 2.0 microns in diameter) are stored into the cell body of macrophages in the vicinity. It is believed, but not completely proven, that fibroblasts taking up and storing the ink particles move poorly and are almost fixed in the connective tissue. The tattoo therefore does not change markedly (17). Does it mean that a fibroblast has the same life expectancy than us? If not, when the fibroblast containing the tattoo particle is dying what are the biological messages making a young fibroblast come at the same place and incorporate the tattoo particles? This answer is still open.

Melanosomes, like tattoo particles, are little targets with a thermal relaxation time around 10⁻⁶ sec (18).

The absorption of light pulses by the tattoo pigments is the first and most important step. If there is no absorption, there is no reaction. Immediately after impact, the epidermis looks white which corresponds to gas formation. This whitish colouration disappears spontaneously within minutes. The tattoo pigments absorb the short laser pulses, 10^{-9} sec, so called Q-switched. This produces very high light intensities up to gigawatts. Inside the pigments, this light is converted into heat within nanoseconds, producing an increase in temperature above 1000 °C (photothermal effect). This rapid thermal expansion produces shock waves and a potential localized cavitation, so called photoacoustic shock which leads to a particle fragmentation and selective death of pigment containing cells. There is also at the same time a breaking in the chemical bonds inside the pigment (photochemical effect). The inflammatory response that follows this process probably engulfs the cells debris as well as the fragmented tattoo pigments. This process of inflammation and phagocytosis might reduce the overall amount of tattoo pigment into the dermis. These particles, as well as their decomposition products, are usually found in regional lymph nodes. Some of the fragmented particles stay in place within the dermis, but as they are redistributed by the laser photoacoustic shock, their dermal scattering coefficient changes and they look less visible to the naked eye as they are located deep in the dermis. Finally, the only part of the pigment which is really eliminated from the body is a very superficial one as it is eliminated by desquamation of epidermis during its repair (19, 20). This phenomenon is called transepidermal elimination.

Based on this knowledge, the first real nonscarring tattoo removal was demonstrated in Scotland by Reid et al. (21). Later on other teams refined the technique and used other Q-switched lasers (22, 23).

Benefits of the use of Q-switched lasers

It is well established that the Q-switched lasers are the gold standard in lasers to remove tattoos (Figs. 1 and 2). Four wavelengths are available: double frequency Nd:YAG at 532 nm, ruby at 694 nm, alexandrite at 755 nm and Nd:YAG at 1064 nm. Pulse duration is usually between 10 and 100 nsec. Blue-black, carbon based, amateur tattoos respond best, in 3 to 5 sessions either to Q-switched ruby, alexandrite or Nd:YAG, while professional tattoos containing more pigment of various composition could require 10 to 15 sessions (24, 25). Traumatic tattoos, such as gravel particles can also be treated (26). Caution must be taken with gunpowder or fireworks tattooed debris as the laser impact can cause a microexplosion into the skin and provoke pox-like scars and the dispersion of pigment (27–28). Double frequency Nd:YAG at 532 nm is more suitable for removing red colour tattoos (29). Q-switched ruby (694 nm) and alexandrite (755 nm) are more efficient in removing green and blue colours than Q-switched Nd:YAG (1064 nm) (30).

Recently, new indications have been described for the use of Q-switched lasers. Removing amalgam tattoos, which consist of the deposition of metallic particles (eg, silver, mercury, copper, zinc, and tin) into

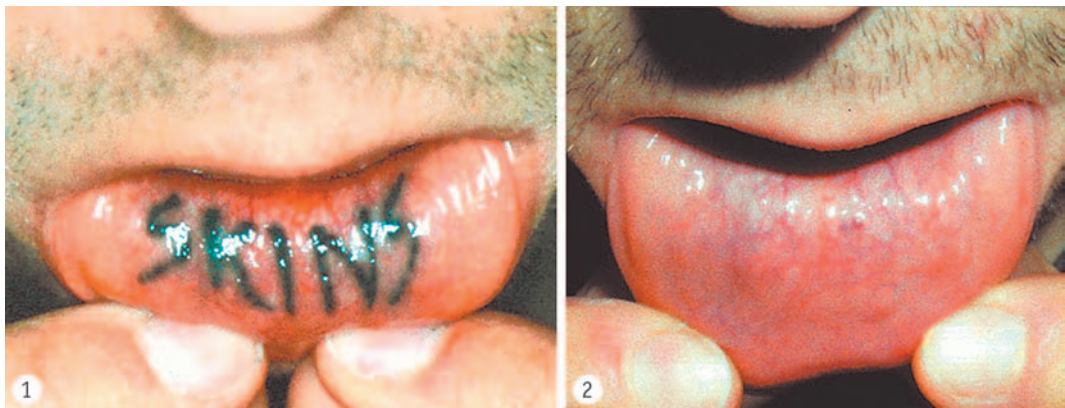

Fig. 1. Blue-black amateur tattoo on inner side of lower lip.

Fig. 2. Complete clearance after 6 sessions with Q-switched Nd:YAG laser at 1064 nm.

the oral mucosa with the Q-switched alexandrite (31). This indication will also work well with Q-switched ruby or Nd:YAG. Clearing up brown discolorations after parenteral iron injections (32). Some various hyperpigmentations have also been successfully tried – postsclerotherapy (33), antimalarial (34) and imipramine (35) hyperpigmentations. Another form of hyperpigmentation, due to minocyclin intake, has also been improved by the Q-switched ruby (36).

Caveats with the use of Q-switched lasers

The vast majority of caveats with the use of Q-switched lasers are due to pigments. If the pigments used were only made with carbon, such as Indian ink, charcoal, or magnetite (Fe_3O_4), the vast majority of problems would be avoided. Tattoo inks are the least-regulated substances injected into people within our society. No law exists regarding their purity, pharmacology or biodistribution. As with any new ink, it could have possible devastating unknown new side effects and could be put on the market at any time due to this lack of regulation, European countries as well as Switzerland are starting to react and will soon propose guidelines which may become law (37).

Generally tattoo pigments are well tolerated by the skin if we look at the millions of tattoos done yearly in the world and the quite low rate of complications. However, there is no obligation to report by law any side effects due to tattooing. Consequently, there is no real survey available for the public health community. Nevertheless, adverse reactions are well known, the most frequent being allergies, some others being due to pigment itself, such as pseudolymphoma or lichenoid reactions. The colours mostly implicated in allergic reactions are red (38, 39), even with organic pigment, yellow, especially if exposed to UV light (40), and green (41). Tattoo pigments have evolved a lot within the last 15 years having had the removal of metallic compounds such as cinnabar, cadmium, chrome cobalt etc. This has diminished, but has not entirely been able to avoid allergic reactions. There is no pigment specifically dedicated for tattooing. People must be aware that they are getting tattooed with pigments made by the chemical industry to dye clothes, paint road signals or car bodies. Finally, the main problem that we are facing are unwanted reac-

tions to pigments when tattoos are being treated by Q-switched lasers. We will divide these adverse reactions into two groups: a) real side effects and b) resistance of pigments to Q-switched lasers.

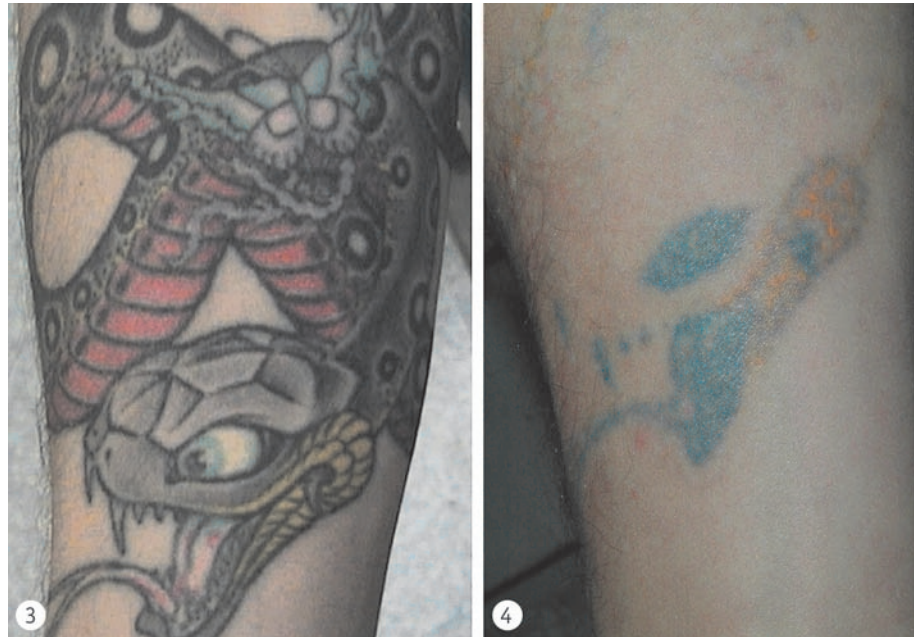Side effects with the use of Q-switched lasers on tattoos

The first side effect published with Q-switched lasers was darkening of the pigment in 1993 (42). One of the possible mechanisms explaining the transformation of a red into a jet black one, is the conversion of ferric oxide (Fe_2O_3) which is red into ferrous oxide (FeO) that is black. This reaction is a pure chemical transformation that has also been obtained in vitro, on an agar petri dish. The intracellular milieu does not play a role in this chemical transformation. Since 1993 published paper, many other publications have reported tattoo ink darkening (43, 44). Any tattoo pigment can darken not only flesh ones, into any colour, e.g a red tattoo might darken to green, which will be very resistant to removal (see below). This darkening phenomenon has become so frequent that every time we have to deal with removing a tattoo on a visible area (e.g. the face) we will first propose a test spot on a covered area. The patient has to go back to the tattoo shop and ask for the same pigment to be tattooed in the axilla. After a month, a Q-switched laser test spot is performed on this limited area. If darkening occurs then the face is of course not treated. The test spot can easily be removed by surgical excision with a minimal visible scar. When darkening occurs it is usually difficult to remove the darkened pigment (Figs. 3 and 4). It requires the use of multiple lasers, Q-switched or even ablative ones, Ultrapulse CO_2 (UPCO₂) or pulsed Erbium-YAG (45). Sometimes darkening can be used as a therapeutic advantage (46). Another possible mechanism for explaining darkening is the possible role of titanium dioxide (47). This compound, which is an increasingly popular white ink, is used to enhance the brilliance of tattoos (48).

Another frequent side effect is scarring following treatment of multiple layered tattoos (49). Many tattooed people have “double” tattoos, that is so to say that a second tattoo is used to cover the first one which the patient may not have liked. Finally he (she) dislikes even the final design and wants everything to

Fig. 3. Multicolour professional tattoo on a forearm. Patient did not know that the tongue and the eye were tattooed with flesh colour.

Fig. 4. Despite 12 sessions with Q-switched Nd:YAG laser at 532 nm and 1064 nm darkening still persists. Also note that yellow colour resists treatment. This was mentioned to the patient before starting laser removal.



be removed. This technique is called “retattooing” (50). But he (she) often forgets that the final tattoo in fact covers another one. Patients with a tattoo should always be asked if they have a retattooed motif. The scarring phenomenon occurs probably because of the high density of pigment in this type of tattoo and the very strong absorption of energy by it. This produces heat so intense that it causes damage even to the surrounding dermis. Retattooing can also be a possible cause of resistance to pigment as both tattoos have not been done at the same time by the same artist. Different pigments have been used, increasing the difficulty of removal by Q-switched lasers.

Allergy to pigments has already been briefly discussed. Sometimes allergy to red pigment can successfully be treated by removing the pigment by Q-switched laser at 532 nm (51) (Figs. 5, 6 and 7). This will also remove the tenderness as well as the itching due to the allergy. But one must be aware of possible rare allergic reaction after using the Q-switched laser, either immediate (52) or delayed (53). The possible mechanism of these allergies is that the fragmented tattoo particles have been expelled from the intracellular compartment where they usually are. Becoming extra-cellular and possibly modified by the laser impact they are recognised as a foreign body. The physician dealing with removing tattoos with Q-switched

lasers must always be aware of these possible allergic reaction after laser treatment and be ready to manage them.

A last rare complication is the appearance of a chrysiasis after laser therapy. Chrysiasis is a blue-gray skin discoloration that occurs in sun-exposed areas of some patients who receive gold salt. Localized chrysiasis after the use of Q-switched laser for treatment of post-inflammatory hyperpigmentation has been reported (54). The Q-switched laser impacts resulting in structural alteration of the gold deposits which is similar to what happens after UV-exposure. This results in a blue-gray colouration on the area treated with the laser. This situation can be improved by the use of long-pulsed laser (normal mode ruby laser) (55).

Resistance of pigments to Q-switched lasers

Resistance of pigment to available lasers is a key problem. As already mentioned 4 different wavelengths are available for Q-switched lasers: 532nm, 694 nm, 755 nm and 1064 nm. The laser wavelength must be absorbed by the pigment to interact with it and promote the photoacoustic shock already described. If there is no absorption, nothing will happen. A recent study by Bäumlner (56) on composition of tattoo pigment

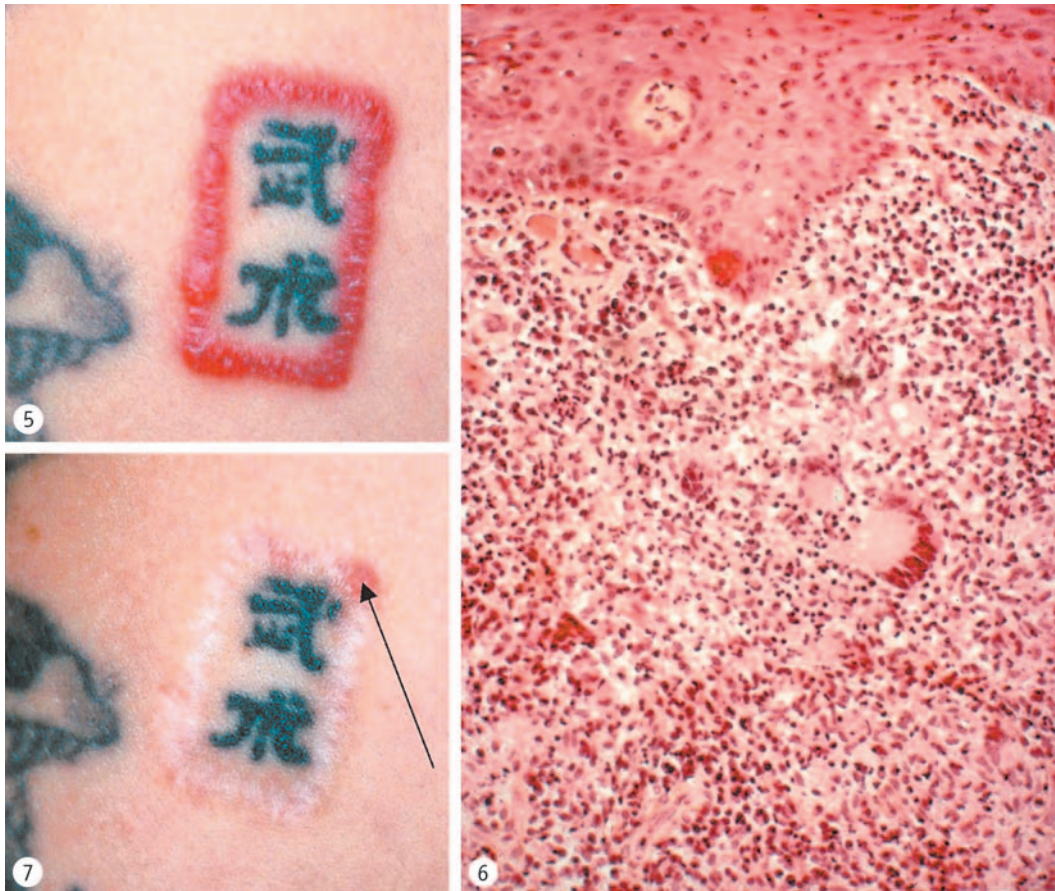


Fig. 5. Allergy to red pigment.

Fig. 6. Biopsy (H&E 40 \times) showing intense acute inflammation into the dermis associated with chronic, demonstrated by giant granulomatous cells.

Fig. 7. Result after 6 sessions of Q-switched Nd:YAG laser at 532 nm. Note good pigment removal but atrophic scar due to chronic inflammation. Arrow shows biopsy site.

showed that some colours, like yellow, have their absorption peak in a range where no laser exists, at 480 nm. It is no wonder why yellow pigments respond so poorly to Q-switched laser treatment. Over the 41 coloured substances analysed, 16 represented individual chemicals of structured well-known organic pigments. The problem is that these different chemical compounds are mixed together, with very often the addition of titanium dioxide, to create a coloured substance which will be used by the tattoo artist. Very often he or she will mix these already complex compounds with other complex pigments to obtain the final colour. Two tattooed colours which look similar can be made with two completely different compounds. Transmission electron microscopy (TEM)

from the same pigment can show particles of completely different size and shape, depending on the tattoo supplier. When we know that Q-switched lasers work by interacting at a physico-chemical level with tattoo particles we can conclude that it is simply impossible to guess which tattoo will respond in a favourable manner to Q-switched laser only by looking at it. The mixture of different compounds and the addition of titanium dioxide make modern, recent decorative tattoos more resistant to laser removal.

The management of these resistant pigments should be explained very clearly to the patient and should be made aware that some colours may resist, especially yellow, green and blue, and some could darken and then resist, especially flesh ones. In case

of a multi-colour tattoo treatment it is best to perform first a spot test on suspicious areas (57). It is of course best to choose a motif which will have no resistant or potentially darkened area. If this is not possible, these non-responsive areas should be very limited in size – less than 10% of the total surface of the tattoo. If it is larger than 10%, it is best not to start with the Q-switched laser treatment at all, for economical reasons. Other techniques (surgical, chemical) can then be chosen on a primary intention, knowing that they will leave scarring and dyschromia behind. When we are facing with a limited area which has resisted or has darkened, we usually choose to treat these areas with a combination of ablative lasers, UP_{CO}₂ and pulsed Erbium-YAG (Figs. 8, 9 and 10). This is a multiple session treatment. At each session an ablation of 100–200 microns is performed with the Er-

bium-YAG laser. The UP_{CO}₂ is used sparingly to coagulate dermal blood vessels when necessary. This will remove a good amount of the pigment included in this thickness by transepidermal elimination. A case report has recently been published in this direction with the use of the UP_{CO}₂ only for removing a lip-liner tattoo (58). Reepithelisation is promoted the same way as after a resurfacing. Each session is spaced 1–3 months apart, each session trying to go a little deeper than the previous one. Due to the very limited amount of thermal damage created by the Erbium-YAG laser, it is possible to end up with a good global percentage of pigment removal and an acceptable final scar. The fibrosis occurring with scarring alters the dermal scattering coefficient resulting in obscuring of deeper pigment also contributing to enhance results (19). Caution should be taken not to per-

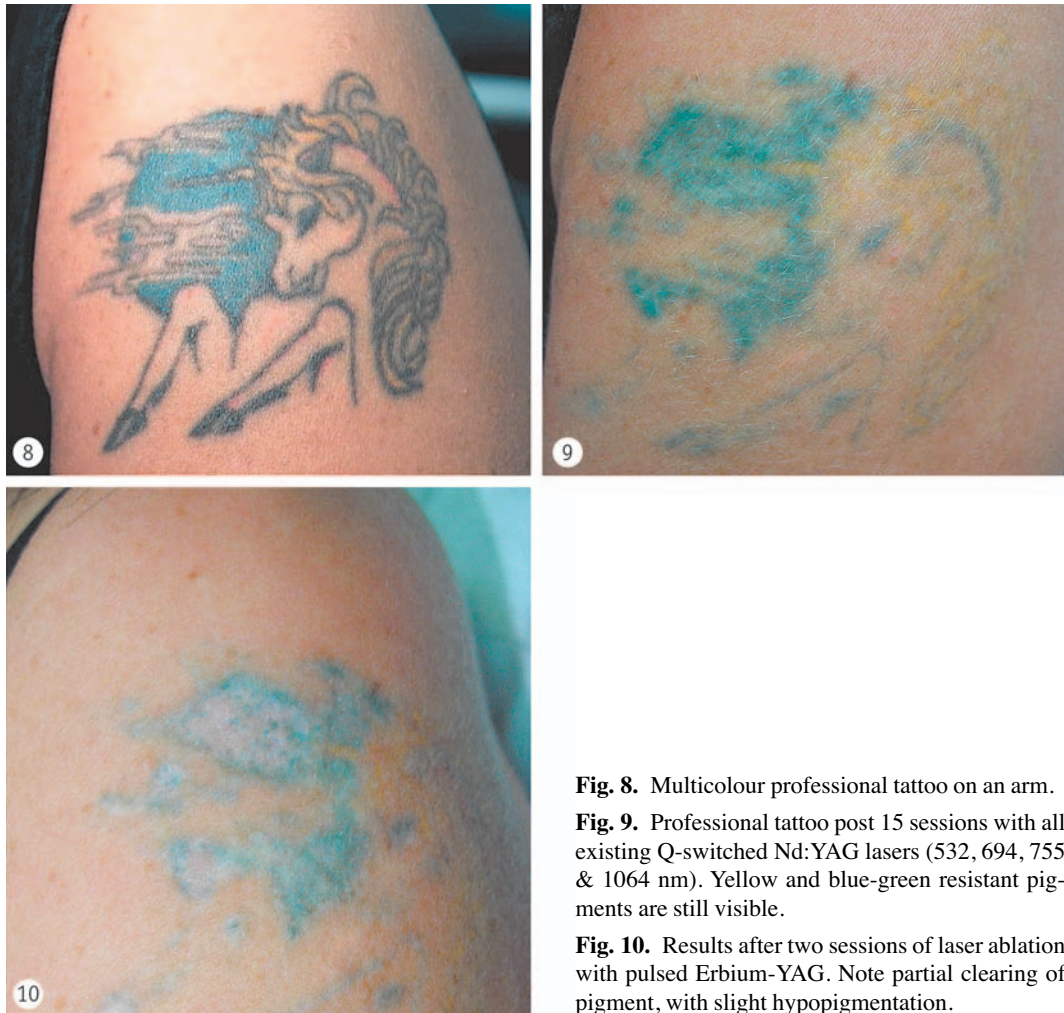


Fig. 8. Multicolour professional tattoo on an arm.

Fig. 9. Professional tattoo post 15 sessions with all existing Q-switched Nd:YAG lasers (532, 694, 755 & 1064 nm). Yellow and blue-green resistant pigments are still visible.

Fig. 10. Results after two sessions of laser ablation with pulsed Erbium-YAG. Note partial clearing of pigment, with slight hypopigmentation.

form ablation too deeply by trying to remove all pigment at each session to avoid vicious scars.

Future

We see three main ways to improve the future for unwanted or complications from tattoos:

1. Improving the clearance of tattoo ink particles after laser treatment by better understanding the intimacy with the elimination of pigment. It is not clear yet what are the exact mechanisms of pigment elimination. We know that pigment fragmentation plays a major role but this pigment is rephagocytosed by somatic dermal cells within a few days (19). It becomes “invisible” due to changes in its molecular configuration but it is not really eliminated from the body. Some other mechanisms are involved in pigment elimination like transepidermal elimination and lymphatic transport. Any method which could enhance these ways of pigment elimination would increase clearance. Unfortunately at the present time, the majority of published studies do not succeed to do so (59).

2. Promote the use of safer, chemically well-known pigments, which could be eliminated by available Q-switched laser systems. Firstly it would be a good idea to remove from the market inks which are difficult to remove and which can cause antigenic and or toxic effects. Unfortunately, tattoo inks are very poorly regulated if at all. A swiss taskforce is working on such a possibility and will insist on finding safe inks, which ideally will be harmless to the patient and easy to remove by existing lasers. These inks must of course have good “behaviour” in the skin from a tattooist point of view to bring out a nice design when injected. An interesting idea going in this direction has been recently reported by Huzarai and Anderson (60). They injected into rats’ skin an ink made with magnetite (Fe_3O_4) which is jet-black. It can easily be manipulated by Q-switched lasers as well as external magnetic fields. The tattoos were very stable and healed easily. When they applied a magnetic field for 3 weeks after laser treatment – just by sewing a magnet on the animal’s skin – they could increase significantly the amount of particle accumulated at the area where the magnet was put. In addition, if the epidermis was not intact after the laser treatment, there was an increased amount of eliminated pigment by this

way. It could be possible by choosing the right ink composition and some additional methods, to increase significantly ink removal when laser is performed. It would also reduce the rate of complication due to the use of potentially toxic pigments with or without the use of Q-switched lasers.

3. Optimizing the laser tattoo ink interaction by using pico lasers and thus reducing the number of laser sessions and also improving the final cosmetic aspect. Actual Q-switched assessment for the thousands of people treated by this means. These Q-switched lasers cause a thermal effect on tattoo particles with minimal thermal damage to the surrounding tissue. This is called thermal confinement. After this thermal damage, thermoelastic expansion of the target occurs, resulting in mechanical stress. By confining thermal and photomechanical damage to the target particle, more effective tattoo removal would occur. This is called inertial confinement. To achieve this, each pulse should be delivered within the time in which pressure can be released from the ink particle. This is possible with picosecond (10^{-12} second or trillions of a second) pulse duration. Studies on animals (61) and humans (62) have been performed and they demonstrate that picosecond lasers show a better pigment removal than nanosecond ones. Computer simulations have also been performed and have confirmed that for the same amount of energy delivered, a shorter pulse is more efficient. Consequently the optimal pulse length seems to be approximately 10 to 100 picosecond (63). Laser companies should then be encouraged to develop a picosecond laser for tattoo removal.

Conclusion

Within the last 10 years, Q-switched laser systems have enormously improved the aesthetic result of tattoo removal and we better understand the mechanisms of pigment elimination. But we are now facing another challenge. As tattooing is becoming more and more popular there is an increasing amount of people requesting tattoo removal. With new flashy inks of unknown composition coming onto market, the use of these lasers becomes disappointing for the physician due to potential complications (e.g. darkening) and pigment resistance. On the other hand, people have a tendency to believe in lasers as if they were magic

wands. Some think that with one or two laser sessions any kind of tattoo can be completely and safely removed. It is time now to find pigments which can be injected safely into the skin, without causing any adverse reaction, with or without the use of lasers. Of course, if in the near future any tattoo can be removed safely and easily, tattooing will lose a big part of its symbolism, by not being “for life” anymore. But due to the high percentage of the population being tattooed and having the possibility of choosing a safe and easily removable pigment is also a question of public health.

Tätowierungsentfernung mittels Laser – Vorteile und Vorbehalte

Seit Beginn der Menschheitsgeschichte gibt es Tätowierungen, aber auch den Wunsch, diese zu entfernen. Nachdem viele Jahre lang narbenbildende Verfahren angewendet wurden, kam das Zeitalter der Laser. Anfänglich wegen ihrer Größe und Komplexität aufs Labor beschränkt, verursachten die ersten Systeme noch thermische Schädigungen und damit Narbenbildung und Dyschromie. Im Laufe der letzten 10 Jahre sind gütegeschaltete Lasersysteme zur Anwendung gekommen, die minimale oder keine Schädigungen hinterlassen. Mit diesen Systemen können manche Tätowierungen – je nach verwendeten Pigmenten – ohne Narbenbildung, Hypo- oder Hyperpigmentierungen entfernt werden. Bei Anwendung dieser Laser ist darauf zu achten, dass es nicht zu Komplikationen wie dunkler Hautverfärbung kommt. Auch sollte der Anwender sich darüber im Klaren sein, dass einige Pigmente auf eine Laserbehandlung nicht ansprechen. In unmittelbarer Zukunft sind große Anstrengungen zu unternehmen, um sicherere Farbstoffe zu finden, die gegen eine Behandlung mit den heutzutage üblichen Lasersystemen nicht resistent sind.

Schlüsselwörter

Tätowierung, Pigment, Laser, gütegeschalteter Laser, dunkle Verfärbung, Stoßwelle

Acknowledgement

The author thanks Dr. Wolfgang Bäuml, PhD, Associate Professor at the Department of Dermatology, University of Regensburg, Germany, for his in-depth review of this article. The author is also very grateful to Mrs. Robin Neilson, official secretary of ESLD (European Society for Laser Dermatology), for her enormous help in translating and putting together this article.

References

- ADATTO MA: in: Living Skin – Decorative Tattooing and Dermatology, Editiones Roche Basel, 19 (1993)
- VARMA S, LANIGAN SW: Reasons for requesting laser removal of unwanted tattoos. *Br J Dermatol* 140(3): 483–485 (1999)
- VAN DER VELDEN EM, VAN DER WALLE HB, GROOTE AD: Tattoo removal: tannic acid method of Variot. *Int J Dermatol* 32(5): 376–380 (1993)
- PIGGOT TA, NORRIS RW: The treatment of tattoos with trichloroacetic acid: experience with 670 patients. *Br J Plast Surg* 41: 112–117 (1988)
- BOO-CHAI K: The decorative tattoo: its removal by superficial dermabrasion. *Plast Reconstr Surg* 32: 559–563 (1963)
- MILLER TH, HAY-ROE V: Conventional surgery in techniques of removal tattoos. *Plast Reconstr Surg* 20: 910–914 (1979)
- COLVER GB, CHERRY GW, DAWBER RP, RYAN TJ: Tattoo removal using infra-red coagulation. *Br J Dermatol* 112(4): 481–485 (1985)
- MAIMAN TH: Stimulated optical radiation in ruby. *Nature* 187: 493–494 (1960)
- GOLDMAN L, BLANEY DJ, KINDEL DJ, FRANKE EK: Effect of the laser beam on the skin. *J Invest Dermatol* 40: 121–122 (1963)
- GOLDMAN L, WILSON RG, HORNBY P, MEYER RG: Radiation from a Q-switched ruby laser. Effect of repeated impacts of power output of 10 megawatt on a tattoo of man. *J Invest Dermatol* 44: 69–71 (1965)
- MCBURNIE EI, ROSEN DA: Carbon dioxide laser treatment of verrucae vulgares. *J Dermatol Surg Oncol* 10(1): 45–48 (1984)
- APFELBERG DB, MASER MR, LASH H: Extended clinical use of the argon laser for cutaneous lesions. *Arch Dermatol* 115: 719–721 (1979)
- ARELLANO CR, LEOPOLD DA, SHAFIROFF BB: Tattoo removal: comparative study of six methods in the pig. *Plast Reconstr Surg* 70(6): 609–703 (1982)
- APFELBERG DB, MASER MR, LASH H, RIVERS JL: Progress report on extended clinical use of the argon laser for cutaneous lesions. *Lasers Surg Med* 1: 71–83 (1980)
- APFELBERG DB, LAUB D, MASER MR, LASH H: Pathophysiology and treatment of decorative tattoos with reference to argon laser treatment. *Clin Plast Surg* 7: 369–377 (1980)
- ANDERSON RR, PARRISH JA: Selective photothermolysis: Precise microsurgery by selective absorption of pulsed radiation. *Science* 220: 524–527 (1983)
- FUJITA H, YAMASHITA K, KAWAMATA S, YOSHIKAWA K: The uptake and long-term storage of India ink particles and latex beads by fibroblasts in the dermis and subcutis of mice, with special regard to the non-inflammatory defense reaction fibroblasts. *Arch Histol Cytol* 51(3): 285–294 (1988)
- POLLA LL, MARGOLIS RJ, DOVER WHITAKER D, MURPHY GF, JACQUES SL, ANDERSON RR: Melanosomes are the primary target target of Q-switched ruby laser irradiation in guinea pig skin. *J Invest Dermatol* 89: 281–286 (1987)
- TAYLOR CR, ANDERSON RR, GANGE RW, MICHAUD NA, FLOTTE TJ: Light and electron microscopic analysis of tattoos treated by Q-switched ruby laser. *J Invest Dermatol* 97: 131–136 (1991)
- FERGUSON JE, ANDREW SM, JONES CJ, AUGUST PJ: The Q-switched Nd:YAG lasers and tattoos: A microscopic analysis of laser tattoo interactions. *Br J Dermatol* 137: 405–410 (1997)

21. REID WH, McLEOD PJ, RITCHIE A, FERGUSON-PELL M: Q-switched Ruby laser treatment of black tattoos. *Br J Plast Surg*: 36: 455–459 (1983)
22. TAYLOR CR, GANGE RW, DOVER JS, FLOTTE TJ, GONZALEZ E, MICHAUD N, ANDERSON RR: Treatment of tattoos by Q-switched ruby laser. A dose-response study. *Arch Dermatol* 126: 893–899 (1990)
23. KILMER SL, LEE MS, GREVELINK JM, FLOTTE TJ, ANDERSON RR: The Q-switched Nd:YAG laser effectively treats tattoos. A controlled, dose-response study. *Arch Dermatol*. 129: 971–978 (1993)
24. LEUENBERGER ML, MULAS MW, HATA TR, GOLDMAN MP, FITZPATRICK RE, GREVELINK JP: Comparison of the Q-switched alexandrite, Nd:YAG and ruby lasers in treating blue-black tattoos. *Dermatol Surg*. 25: 10–14 (1999).
25. FITZPATRICK RE, GOLDMAN MP: Tattoos removal using the alexandrite laser. *Arch Dermatol*. 130: 1508–1514 (1994)
26. TROLIUS AM: Effective treatment of traumatic tattoos with a Q-switched Nd: YAG laser. *Lasers Surg Med*. 22: 103–108 (1998)
27. TAYLOR CR: Laser ignition of traumatically embedded fire-work debris. *Lasers Surg Med*. 22: 157–158 (1998)
28. FUSADE T, TOUBEL G, GROGNARD C, MAZER JM: Treatment of gunpowder traumatic tattoo by Q-switched Nd:YAG laser: an unusual adverse effect. *Dermatol Surg* 26: 1057–1059 (2000).
29. KILMER SL, ANDERSON RR: Clinical use of the Q-switched ruby and the Q-switched Nd:YAG laser (1064 nm and 532 nm) for treatment of tattoos. *J Dermatol Surg Oncol*. 19: 330–338 (1993).
30. KUPERMAN-BEADE M, LEVINE VJ, ASHINOFF R: Laser removal of tattoos. *Am J Clin Dermatol*. 2: 21–25 (2001)
31. SHAH G, ALSTER TS: Treatment of an amalgam tattoo with a Q-switched alexandrite (755 nm) laser. *Dermatol Surg*. 28: 1180–1181 (2002)
32. RAULIN C, WERNER S, GREVE B: Circumscribed pigmentations after iron injections-treatment with Q-switched laser systems. *Lasers Surg Med*. 28: 456–460 (2001)
33. TAFAZZOLI A, ROSTAN EF, GOLDMAN MP: Q-switched ruby laser treatment for postsclerotherapy hyperpigmentation. *Dermatol Surg*. 26: 653–656 (2000)
34. BECKER-WEGERICH PM, KUHN A, MALEK L, LEHMANN P, MEGAHED M, RUZICKA T: Treatment of nonmelanotic hyperpigmentation with the Q-switched ruby laser. *J Am Acad Dermatol*. 43: 272–274 (2000)
35. ATKIN DH, FITZPATRICK RE: Laser treatment of imipramine-induced hyperpigmentation. *J Am Acad Dermatol*. 43: 77–80 (2000)
36. FRIEDMAN IS, SHELTON RM, PHELPS RG: Minocycline-induced hyperpigmentation of the tongue: successful treatment with the Q-switched ruby laser. *Dermatol Surg*. 28: 205–209 (2002)
37. PAFAMELETIOU D, ZENIE A, SCHWELA D, BÄUMLER W: Risks and health effects from tattoos, body piercing and related practices. Final draft Ispra May 2003 available on the web at http://europa.eu.int/comm/consumers/cons_safe/news/eis_tattoo_risk_052003_en.pdf
38. MCGROUTHER DA, DOWNIE PA: Reactions to red tattoos. *Br Plast Surg* 30: 84–85 (1977)
39. BENDSOE N, HANSSON C, STERNER O: Inflammatory reactions from organic pigments in red tattoos: *Acta Derm Venereol* (Stockh). 71: 70–73 (1991)
40. BJORNBERG A: Reaction to light in yellow tattoos from cadmium sulfide. *Arch Dermatol*. 88: 83–87 (1962)
41. LOEWENTAL LJA: Reactions in green tattoos. *Arch Dermatol*. 82: 237–243 (1959)
42. ANDERSON RR, GERONEMEUS R, KILMER SL, FARINELLI W FITZPATRICK RE: Cosmetic tattoo ink darkening: a complication of Q-switched and pulsed-laser treatment. *Arch Dermatol* 129: 1010–1014 (1993)
43. VARMA S, SWANSON NA, LEE KK: Tattoo ink darkening of a yellow tattoo after Q-switched laser treatment. *Clin Exp Dermatol*. 27: 461–463 (2002)
44. CHANG SE, KIM KJ, CHOI JH, SUNG KJ, MOON KC, KOH JK: Areolar cosmetic tattoo ink darkening: a complication of Q-switched alexandrite laser treatment. *Dermatol Surg* 28: 95–96 (2002)
45. FITZPATRICK RE, LUPTON J: Successful treatment of treatment-resistant laser-induced pigment darkening of a cosmetic tattoo. *Lasers Surg Med*. 27: 358–361 (2000)
46. CASPARIAN JM, KRELL J: Using a side effect to therapeutic advantage: the darkening of red eyebrow tattoo pigment following Q-switched laser treatment. *Dermatol Surg*. 26: 255–258 (2000)
47. ROSS EV, YASHAR S, MICHAUD N, FITZPATRICK R, GERONEMEUS R, TOPE WD, ANDERSON RR: Tattoo darkening and non-response after laser treatment: a possible role for titanium dioxide. *Arch Dermatol*. 137: 33–37 (2001)
48. LEHMANN G, PIERCHALLA P: Tattooing dyes. *Dermatosen Beruf Umwelt*. 36: 152–156 (1988)
49. ALORA MBT, ARNDT KA, TAYLOR CR: Scarring following Q-switched laser treatment of “double tattoos”. *Arch Dermatol*. 136: 269–270 (2000)
50. ADATTO MA: in: *Living Skin – Decorative Tattooing and Dermatology*, Editiones Roche Basel 1993, 84–86
51. DAVE R, MAHAFFEY PJ: Successful treatment of an allergic reaction in a red tattoo with the Nd-YAG laser. *Br J Plast Surg*. 55: 456 (2002)
52. ENGLAND RW, VOGEL P, HAGAN L: Immediate cutaneous hypersensitivity after treatment of tattoo with Nd:YAG laser: a case report and review of the literature. *Ann Allergy Asthma Immunol*. 89: 215–217 (2002)
53. ASHINOFF R, LEVINE VJ, SOTER NA: Allergic reactions to tattoo pigment after laser treatment. *Dermatol Surg*. 21: 291–294 (1995)
54. TROTTER MJ, TRON VA, HOLLINGDALE J, RIVERS JK: Localized chrysiasis induced by laser therapy. *Arch Dermatol*. 131: 1411–1414 (1995).
55. YUN PL, ARNDT KA, ANDERSON RR: Q-switched laser-induced chrysiasis treated with long-pulsed laser. *Arch Dermatol*. 138: 1012–1014 (2002)
56. BÄUMLER W, EIBLER ET, HOHENLEUTNER U, SENS B, SAUER J, LANDTHALER M: Q-switch laser and tattoo pigments: first results of the chemical and photophysical analysis of 41 compounds. *Lasers Surg Med*. 26: 13–21 (2000)

57. TIMKO AL, MILLER CH, JOHNSON FB, ROSS EV: In vitro quantitative chemical analysis of tattoo pigments. *Arch Dermatol.* 137: 143–147 (2001)
58. MAFONG EA, KAUVAR AN, GERONEMUS RG: Surgical pearl: Removal of cosmetic lip-liner tattoo with the pulsed carbon dioxide laser. *J Am Acad Dermatol.* 48: 271–272 (2003)
59. ORT RJ, ANDERSON RR, ARNDT KA, DOVER JS: CO₂ laser resurfacing of tattoos prior to Q-switched laser treatment (abstract). *Lasers Surg Med.* 26 (suppl 12): 23 (2000)
60. HUZARAI M, ANDERSON RR: Magnetite tattoos. *Lasers Surg Med.* 31: 121–128 (2002)
61. HERD RM, ALORA MB, SMOLLER B, ARNDT KA, DOVER JS: A clinical and histologic perspective prospective controlled comparisons study of the picosecond titanium sapphire (795nm) laser versus the Q-switched alexandrite (752 nm) laser for removing tattoo pigment. *J Am Acad Dermatol.* 40: 603–606 (1999)
62. ROSS V, NASEEF G, LIN G, KELLY M, MICHAUD N, FLOTTE TJ, RAYTHEN J, ANDERSON RR: Comparison of responses of tattoos to picosecond and nanosecond Q-switched neodymium: YAG lasers. *Arch Dermatol.* 134: 167–171 (1998)
63. HO DDM, LONDON R, ZIMMERMAN GB, YOUNG DA: Laser-tattoo removal—a study of the mechanism and the optimal treatment strategy via computer simulations. *Lasers Surg Med.* 30: 389–397 (2002)

Correspondence address:

Maurice A. Adatto, Medical Director, Skinpulse Dermatology Centre, 5, Rd-Pt Plainpalais, 1205 Geneva, Switzerland; Tel.: ++4122-329 7000, Fax: ++4122-320 80 88, e-mail: maurice.adatto@skinpulse.ch